


Role of DCB Plus Provisional Stenting in Treating Complex Lesions

Reactions from experts on IN.PACT Global data and what they mean for treatment options.

**WITH GARY M. ANSEL, MD, FACC; JOHN R. LAIRD, MD; GUNNAR TEPE, MD, PhD;
AND THOMAS ZELLER, MD, PhD**



This past winter at the Leipzig Interventional Course (LINC) 2018, I presented the first comparison data from the IN.PACT Global study between patients treated with a stand-alone IN.PACT™ Admiral™ drug-coated balloon (DCB) (Medtronic) and those treated using an IN.PACT Admiral DCB with provisional stenting. IN.PACT Global enrolled more than 1,500 patients and had an overall provisional stent rate of 25.3%.¹ Comparing the 1,044 nonstented DCB patients with the 353 patients who did receive stents afforded a statistically meaningful retrospective examination to gain insight into questions many interventionalists have regarding DCB use: “When do I need a stent?” and “What will be the outcomes if I do stent?” Ideally, we’d like to have data derived from randomized controlled trials (RCTs) for these types of questions, but in the absence of those data, IN.PACT Global gives us the first high-quality glimpse into factors affecting provisional stent use and anticipated outcomes with the IN.PACT Admiral DCB.

Baseline clinical characteristics between the IN.PACT Global stented and nonstented cohorts were fairly well matched, but the cohorts diverged considerably when examining baseline lesion characteristics. The stented lesions demonstrated longer lengths, more total occlusions, longer occluded lengths, higher grade stenoses, and more severe calcification than the nonstented lesions. This is not surprising considering the operators at the time of the procedure were more likely using provisional stents to treat the more complex nature of the lesion, most often using stenting to mitigate recoil and dissection. Surprisingly, after 2 years of follow-up, rates of freedom from clinically driven target lesion revascularization (CD-TLR) were not statistically different with the stented and nonstented cohorts (Kaplan-Meier estimate of 80.8% and 83.9%, respectively).¹ Furthermore, no differences in safety outcomes were observed.

The take-away messages here are that provisional stenting plays a key role in DCB treatment of long, complex disease and that IN.PACT Admiral DCB used in conjunction with provisional stenting demonstrates consistent outcomes at 2 years despite vastly different lesions. In this article, I am joined by my esteemed peers for their reflections on these outcomes.

— Gary M. Ansel, MD, FACC

Provisional stenting following balloon angioplasty to treat significant elastic recoil or flow-limiting dissection is a necessary consequence of balloon angioplasty. RCTs with percutaneous transluminal angioplasty (PTA) control groups have demonstrated provisional stent rates from as low as 6.9% (LEVANT 2) to as high as 50.4% (ZILVER PTX).²⁻⁴ In the IN.PACT SFA Trial, provisional stenting was necessary in 12.6% of cases in the PTA arm and 7.3% of cases in the DCB arm of the trial.⁵ Provisional stenting rates rise with increasing lesion complexity, as seen in the IN.PACT Global study.¹ The efficacy of DCB with provisional stent implantation was not well elucidated until recently.

The IN.PACT Global study enrolled 1,535 patients at 64 sites

around the world. There was independent adjudication by a clinical events committee and prospective subset analysis with core lab-reported results. There was a 25.3% provisional stent rate in the IN.PACT Global study with the following reasons for stenting: persistent residual stenosis $\geq 50\%$ (59.2%), flow-limiting dissection (53.6%), translesion pressure gradient ≥ 10 mm Hg (0.5%), or other (5.1%). Not surprisingly, lesion lengths were greater in the stented versus nonstented group (15.37 vs 10.97 cm). Additionally, total occlusions were almost twice as common (54.7% vs 28.6%), and severe calcification was more frequently present (14.7% vs 8.7%) in the stented versus nonstented group, respectively. When provisional stenting was required, spot stenting

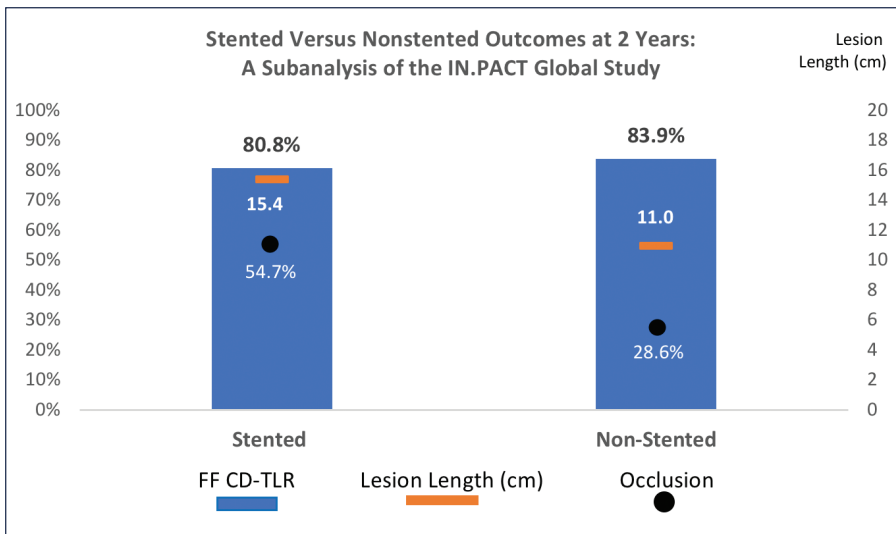


Figure 1. IN.PACT Global subanalysis of stented versus nonstented patients at 2 years. Abbreviations: FF CD-TLR, freedom from clinically driven target lesion revascularization.

Freedom from CD-TLR in the stented group at 1 and 2 years was excellent (92.1% and 80.8%) and did not differ from the nonstented group despite the increased complexity of lesions in the stent group.

— John R. Laird, MD

(24.4%) or partial lesion coverage (37.8%) were performed in the majority of cases, thus avoiding the dreaded full metal jacket. Freedom from CD-TLR in the stented group at 1 and 2 years was excellent (92.1% and 80.8%) and did not differ from the nonstented group despite the increased complexity of lesions in the stent group (Figure 1). There were no differences between the stented and nonstented groups with regards to any of the safety outcomes.¹

—John R. Laird, MD

What are your impressions of these data and have they changed your daily practice?

Dr. Laird: I find these data very useful and reassuring. They support the approach that I have adopted in my own clinical practice using DCB angioplasty as a primary treatment strategy for almost all femoropopliteal lesions, followed by provisional stenting as necessary

for suboptimal DCB results. When stenting is required, spot stenting or use of stents shorter than the original lesion length are employed. With careful technique and prolonged balloon inflations, the rate of provisional stenting can be surprisingly low even in complex lesions. Nonetheless, it is reassuring to know that there is no “downside” with regard to safety and long-term patency when provisional stenting is performed.

Prof. Tepe: These are great data showing a low TLR rate with the IN.PACT Admiral DCB. Even in more complicated and longer lesions

where a stent was needed, the same outcome as stand-alone IN.PACT Admiral DCB can be reached if stents are placed after the IN.PACT Admiral DCB is used.¹ For me, this means that a decision around the question, “Is this a primary PTA/DCB patient or will this be a stent patient?” is not mandatory. I can start with the decision to use an IN.PACT Admiral DCB in order to enhance the patency. In cases where a stent is necessary, the outcome is the same with the combination therapy; therefore, a decision about a stent can be made later. This will allow me to use fewer stents.

Additionally, aside from all the subgroups, the long-term data of the IN.PACT SFA Trial are very important to me because they show that we can either prevent or delay a TLR by using IN.PACT Admiral DCBs.⁶⁻⁸

Prof. Zeller: First, stenting does not negatively impact longer-term outcomes of DCB angioplasty. This was an initial concern regarding stent implantation following DCB angioplasty due to the chronic outward force of the nitinol stent applied to the vessel wall, potentially creating chronic vessel trauma. It was unknown if this trauma may overcome the short-term effect of the antiproliferative drug applied by the DCB. Second, DCBs represent a vehicle for drug transfer and do not resolve the general limitations of balloon angioplasty such as mechanical recoil and dissection. Even if we favor the approach of “leave nothing behind,” stents are essential to salvage acute treatment success in lesions with increased complexity, as shown in the study. Lesions receiving a stent were longer, more calcified, and had a higher percentage of chronic total occlusions (CTOs). Third, the analysis demonstrates that an optimal DCB result, which was present in nearly three out of four cases, does not deserve stent placement.

[These data] support the approach that I have adopted in my own clinical practice using DCB angioplasty as a primary treatment strategy for almost all femoropopliteal lesions, followed by provisional stenting as necessary for suboptimal DCB results.

– John R. Laird, MD

In regard to daily practice, the lesson learned is that a good DCB result, even in complex femoropopliteal lesions including the entire popliteal artery, does not need a scaffold to achieve outstanding clinical results. However, selective stent placement does salvage insufficient balloon and DCB angioplasty outcomes and results in the same 2-year performance as compared with lesions treated with plain DCB angioplasty. This study outcome has the potential to reduce costs for the treatment of complex femoropopliteal lesions.

Dr. Ansel: These types of real-world data from a multicenter study with independent adjudication are important. Regulatory trials are typically completed in such restricted populations that generalization to the more commonly treated patients can often be difficult for the practicing physician. We have wondered how effective DCBs are in complex disease, where we often need to optimize with stents, and now we know DCBs can be very valuable. Providing 2-year outcomes in complex disease by optimizing with provisional stents equal to stand-alone DCBs for simple disease is a great outcome. We currently have compelling 5-year data from the Zilver PTX drug-eluting stent (DES) (Cook Medical),⁹ but evaluating bare-metal stent (BMS) use after DCB therapy is important as we try to compare the two treatment modalities.

In my opinion, the 5-year DES data support its expanded use in femoropopliteal disease treatment. Now, with evolving DCB data, especially in conjunction with provisional stent use for the treatment of long, complex disease, we have additional evidence supporting further

adoption of drug technologies. These are very promising results but we still are chasing the types of outcomes we see in the coronary vessels. I hope continued investment, research, development, and improvements are still on the horizon.

How do the DCB plus provisional stenting data compare with the results of the BMS results in long lesions?

Dr. Laird: The results of DCB plus provisional stenting from the IN.PACT Global study compare very favorably with the results of BMS for long lesions in the published literature. In the recently published TIGRIS trial, two different bare-nitinol stents (Tigris vascular stent, Gore & Associates; LifeStent, BD Interventional) were compared for similar-length superficial femoral artery (SFA) lesions (10.8 and 11.8 cm, respectively).¹⁰ Freedom from TLR at 2 years for the Tigris and LifeStent were 70.5% and 67.2%, respectively, compared with the 2-year freedom from TLR rate of 80.8% for the IN.PACT Global stent group.^{1,10}

What do you see as the benefits or drawbacks of DCB plus provisional stenting in comparison to a primary BMS approach?

Prof. Zeller: A primary BMS full metal jacket approach, particularly in long lesions, is characterized by reduced patency rates and an increased risk for stent fractures.^{11,12} DCB angioplasty plus provisional stent placement potentially reduces both risks. The only indication for a full metal jacket is the severely calcified CTO, which would indicate the need for a dedicated interwoven stent offering high compression resistance.

Dr. Laird: There are a number of pitfalls to the primary BMS approach to femoropopliteal lesions. Long-segment SFA stenting is associated with higher restenosis rates as well as higher rates of stent fracture. In the TIGRIS trial, use of the LifeStent for long SFA lesions was associated with a 32.7% fracture rate at 2 years.¹⁰ Many of these fractures were complex grade 4 and 5 fractures. There is a growing understanding that a primary BMS approach that leads to full metal jacket stenting is not a desirable outcome.

The Viabahn stent graft (Gore & Associates) has been shown to be an effective alternative for long femoropopliteal lesions and was shown to be superior to BMSs for long lesions in the VIASTAR trial. In the VIASTAR trial, 1-year freedom from CD-TLR was 84.6% following treatment of long lesions with the Viabahn stent graft (mean lesion length, 19.0 cm).¹³ In the IN.PACT Global study, 1-year freedom from CD-TLR following treatment of patients treated in the stented group (mean lesion length, 15.37 cm) was 92.1%.¹ Despite favorable

outcomes with the Viabahn stent graft compared with BMS, there are pitfalls to the use of the Viabahn stent graft. Because the failure mode is often stent graft thrombosis, treatment of Viabahn failure is more complicated and entails the use of thrombolytic agents and thrombectomy devices.

From your experience, what are the advantages/disadvantages of the DCB plus provisional stenting approach in treating CTOs?

Prof. Tepe: This approach allows me to treat CTOs without stents, and in cases where a stent may be needed, I can treat with spot stenting only.

Dr. Ansel: Severely calcified lesions and CTOs are the two most challenging subsets of femoropopliteal disease that we may be faced with treating. These data add support for treating CTOs with DCBs and provisional stenting if necessary. One of the current disadvantages is that Medicare reimbursement does not optimally cover the current cost of treatment for this DCB-based approach, especially for longer lesion disease where multiple balloons and some stenting may occur (even though DCB lengths up to 250 mm are now commercially available to improve this gap).

What are the advantages of using the IN.PACT Admiral DCB versus full metal coverage with a DES?

Dr. Ansel: We recently published our center's experience with the Zilver PTX DES for treating lesion lengths > 20 cm.¹⁴ This was a single-center registry with all the shortcomings and biases that may be present for this type of study, and it was completed before DES devices beyond 8 cm were available. Our experience is that DESs perform better than our historic bare-metal, tubular nitinol stent results but are not as good as the results published on lesion lengths < 20 cm. My personal bias is that very long-segment tubular nitinol stenting is a chronic stimulus for restenosis due to the severe effect on native vessel compliance. This is supported by the improved longer-term restenosis patterns seen in the braided nitinol stent and randomized swirl stent data sets.^{15,16} Full metal coverage may be acceptable as we evolve with future stent lines. The current commodity pricing for BMSs may go away as these newer designs become more widely available.

Prof. Tepe: With the IN.PACT Admiral DCB plus provisional stenting approach, we prevent the full metal coverage, which means in case of a TLR, the procedure may be easier and the outcome may be better. Additionally, the issue of stent fractures is minimized.

Do you think the provisional stent rates could be further lowered by a vessel preparation strategy?

Prof. Tepe: If there is less plaque and calcium burden and less tendency for recoil, a DCB-only strategy may be more successful. Nevertheless, to lower stent rates, the approach of a second long inflation PTA has to be mentioned.

Dr. Ansel: Certainly, there are many variables that lead to stenting. The first is the physician's comfort with the various levels of dissection that may lead to unnecessary stenting. Prolonged balloon inflation, vessel preparation devices, and improved balloon design could all lead to less provisional stenting. However, although we may decrease stenting, I feel there will be cases—especially long lesion disease associated with recoil, significant calcification, and extensive dissection—that will necessitate stents. We see in this data set that stenting appears to be very acceptable, and as we move on to newer generations of improved stent designs, this may even be beneficial as seen in the coronary vessels. The use of expensive vessel preparation, which is not currently universally reimbursed, will require the development of some randomized data sets or those operators may face difficulties as we experience continuing efforts for cost-effective, value-based health care.

What do you see as the strength of DCB plus provisional spot stenting versus partial stenting versus a full metal jacket approach?

Prof. Zeller: A full metal jacket after DCB angioplasty is only indicated if the entire lesion mechanically deserves scaffolding (eg, in some CTOs with severe intraluminal calcification). All other lesion types can be treated with a stent length shorter than the index lesion length (spot or partial stenting). Reducing stent length preserves, at least in part, the natural vessel anatomy and facilitates retreatment if indicated. In-stent restenosis still represents one major challenge of endovascular therapy. In addition, positive vessel remodeling frequently seen after DCB angioplasty, particularly in dissected areas, may lead to incomplete wall apposition of stents, which is a risk factor for acute arterial thrombosis.

What are the implications of these data vis-à-vis a primary DES approach?

Dr. Laird: The ultimate question is how the approach of DCB plus provisional stent implantation compares with the approach of primary DES implantation. We do not currently have sufficient data comparing these two approaches. The landscape is also changing with the addition of a second DES into clinical practice both inside and outside of the United States. Until good comparative

IN.PACT Admiral DCB represents a benchmark even in the European market where almost 20 different DCBs are commercially available.

- Thomas Zeller, MD, PhD

data are available, there will likely be strong advocates for both approaches. One potential downside of the primary DES approach is that it will result in a permanent metal implant in all cases, and in some cases, extensive full metal jacket stenting. For those who favor a “leave nothing behind” or “leave as little behind as possible” strategy, a DCB plus provisional stent strategy will remain popular.

Prof. Zeller: Treatment of complex femoropopliteal lesions with DESs means full lesion coverage with stents; the strategy is to implant DESs from healthy to healthy vessel segments, proximal and distal to a lesion. This impacts the biomechanical properties of the treated vessel with unknown consequences. A primary DES approach can be considered in patients with limited compliance during the intervention in order to keep treatment time as short as possible and elderly patients with limited life expectancy. In younger patients, I would favor leaving less metal behind.

Have these data changed your views on a “leave nothing behind” approach?

Prof. Tepe: No, the data are a confirmation of my approach I followed during the past few years. However, one topic is still unknown. Stents are always placed by the decision of the operator. There are no clear rules. With DCB use, a lot of dissections might be “melted away” because of the remodeling effect of the local drug.¹⁷ Therefore, fewer stents are mandatory compared with what is often used in daily practice, at least in the case of dissections.

Prof. Zeller: In complex lesions, the strategy should be modified into “leave no more behind than necessary.” The good news is that the mechanical durability of modern nitinol stents is significantly improved, and severe stent fractures are no longer a serious concern, which previously was a reason for avoiding stent placement. An alternative for spot or partial stenting could be spot directional atherectomy, in a sense that lesion areas not responsive to

predilatation could be treated with directional atherectomy before DCB inflation as a substitute for spot stenting. This strategy would allow users to still follow a “leave nothing behind” strategy even in most complex lesions.

Dr. Ansel: Although not leaving a prosthetic device behind is often a goal in medical treatments, I personally have been more focused on longer-term clinical outcomes. Now, we have these important data from IN.PACT Global and we see that if we need to treat dissection, recoil, etc., with a stent, the outcomes are similar to optimal DCB results at 2 years. The multiple data sets on DESs even at 5 years have demonstrated low stent fracture rates, a less aggressive pattern of restenosis, and continuing benefit.^{9,18} I think the mantra should be “leave what is best behind” and focus on getting a great up-front result. If that can be done with a stand-alone DCB, great; if that means adding a BMS or using DESs up-front to treat a poor acute result, then the data currently support those choices.

How, if at all, have the data shifted your view toward IN.PACT Admiral DCB as a primary therapy for complex lesions?

Dr. Laird: The excellent results of DCB plus provisional stenting in the IN.PACT Global study should provide reassurance to those interventionalists who have adopted a strategy of primary DCB angioplasty for even the most complex femoropopliteal lesions. If provisional stenting is required, there does not appear to be a negative impact with regards to safety or long-term efficacy. Spot stenting or partial lesion coverage can be performed with the expectation that future TLR rates will be low. The IN.PACT Global study has taught us that DCBs can be effective for long lesions, total occlusions, and complex in-stent restenosis.

Dr. Ansel: These data reinforce our use of the IN.PACT Admiral DCB even in complex long lesion disease. These are very good data sets. Furthermore, although economically troublesome, I am a true advocate for doing what is best for the patient. Although the addition of DCBs up to 250 mm in length may help to manage the cost in patients who historically required multiple shorter balloons, I do hope that the hospitals, Medicare, and other payors can identify pathways to optimize the physician drivers as well.

Prof. Tepe: Based on the large amount of data from the IN.PACT Global study, I am confident that this DCB can be used as a primary strategy in almost every patient. It is our primary choice in the SFA and femoropopliteal artery.

Prof. Zeller: The data simply confirm and justify my own treatment strategy I have followed since the very beginning

of the DCB era: Not withholding from patients the potential benefits of DCBs, independent of the TASC classification of the lesion. Simple lesions, mainly TASC A and B, perform well with stand-alone DCB angioplasty;^{5,6,19} however, even complex TASC C and D lesions show excellent 2-year outcomes if the DCB is combined with provisional stent placement.^{7,8,20} IN.PACT Admiral DCB represents a benchmark even in the European market where almost 20 different DCBs are commercially available. ■

1. Ansel GM. Stented versus non-stented outcomes at 2 years: a sub-analysis of the IN.PACT Global study. Presented at the 2018 Leipzig Interventional Course (LINC 2018); January 30–February 2, 2018; Leipzig, Germany.
2. Rosenfield K, Jaff MR, White CJ, et al. Trial of a paclitaxel-coated balloon for femoropopliteal artery disease. *N Engl J Med*. 2015;373:145–153.
3. Laird JR, Katzen BT, Scheinert D, et al. Nitinol stent implantation versus balloon angioplasty for lesions in the superficial femoral artery and proximal popliteal artery: twelve-month results from the RESILIENT randomized trial. *Circ Cardiovasc Interv*. 2010;3:267–276.
4. Dake MD, Ansel GM, Jaff MR, et al. Paclitaxel-eluting stents show superiority to balloon angioplasty and bare metal stents in femoropopliteal disease: twelve-month results from the RESILIENT randomized trial. *Circ Cardiovasc Interv*. 2011;4:495–504.
5. Tepe G, Laird J, Schneider P, et al. Drug-coated balloon versus standard percutaneous transluminal angioplasty for the treatment of superficial femoral and popliteal artery disease: 12-month results from the IN.PACT SFA randomized trial. *Circulation*. 2015;131:495–502.
6. Schneider PA, Laird JR, Tepe G, et al. Treatment effect of drug-coated balloons is durable to 3 years in the femoropopliteal arteries: long-term results of the IN.PACT SFA randomized trial. *Circ Cardiovasc Interv*. 2018;11:e005891.
7. Micari A, Brodmann M, Keirse K, et al. Drug-coated balloon treatment of femoropopliteal lesions for patients with

- intermittent claudication and ischemic rest pain: 2-year results from the IN.PACT Global study. *JACC Cardiovasc Interv*. 2018;11:945–953.
8. Micari A, Nerla R, Vadalà G, et al. 2-year results of paclitaxel-coated balloons for long femoropopliteal artery disease: evidence from the SFA-Long study. *JACC Cardiovasc Interv*. 2017;10:728–734.
9. Dake MD, Ansel GM, Jaff MR, et al. Durable clinical effectiveness with paclitaxel-eluting stents in the femoropopliteal artery: 5-year results of the Zilver PTX randomized trial. *Circulation*. 2016;133:1472–1483.
10. Laird J, Zeller T, Loewe C, et al. Novel nitinol stent for lesions up to 24 cm in the superficial femoral artery and proximal popliteal artery: 24-month results from the TIGRIS randomized trial. *J Endovasc Ther*. 2018;25:68–78.
11. Hong S-J, Ko Y-G, Shin D-H, et al. Outcomes of spot stenting versus long stenting after intentional subintimal approach for long chronic total occlusions of the femoropopliteal artery. *JACC Cardiovasc Interv*. 2015;8:472–480.
12. Lin Y, Tang X, Fu W, et al. Stent fractures after superficial femoral artery stenting: risk factors and impact on patency. *J Endovasc Ther*. 2015;22:319–326.
13. Lammer J, Zeller T, Hausegger KA, et al. Heparin-bonded covered stents versus bare-metal stents for complex femoropopliteal artery lesions: the randomized VIASAR trial (Viabahn endoprosthesis with PROPATEN bioactive surface [VIA] versus bare nitinol stent in the treatment of long lesions in superficial femoral artery occlusive disease). *J Am Coll Cardiol*. 2013;62:1320–1327.
14. Phillips JA, Falls A, Kolluri R, et al. Full drug-eluting stent jacket: two-year results of a single-center experience with Zilver PTX stenting for long lesions in the femoropopliteal arteries. *J Endovasc Ther*. 2018;25:295–301.
15. Bishu K, Armstrong EJ. Supera self-expanding stents for endovascular treatment of femoropopliteal disease: a review of the clinical evidence. *Vasc Health Risk Manag*. 2015;11:387–395.
16. Zeller T, Gaines PA, Ansel GM, Caro CG. Helical centerline stent improves patency: two-year results from the randomized Mimics trial. *Circ Cardiovasc Interv*. 2016;9:e002930.
17. Tepe G, Zeller T, Schnorr B, et al. High-grade, non-flow-limiting dissections do not negatively impact long-term outcome after paclitaxel-coated balloon angioplasty: an additional analysis from the THUNDER study. *J Endovasc Ther*. 2013;20:792–800.
18. Müller-Hülsbeck S, Keirse K, Zeller T, et al. Long-term results from the MAJESTIC trial of the Eluvia paclitaxel-eluting stent for femoropopliteal treatment: 3-year follow-up. *Cardiovasc Intervent Radiol*. 2017;40:1832–1838.
19. Laird JR, Schneider PA, Tepe G, et al. Durability of treatment effect using a drug-coated balloon for femoropopliteal lesions: 24-month results of IN.PACT SFA. *J Am Coll Cardiol*. 2015;66:2329–2338.
20. Brodmann M, Keirse K, Scheinert D, et al. Drug-coated balloon treatment for femoropopliteal artery disease: the IN.PACT Global study de novo in-stent restenosis imaging cohort. *JACC Cardiovasc Interv*. 2017;10:2113–2123.

PARTICIPANTS



Gary M. Ansel, MD, FACC

System Medical Chief, Vascular Services
OhioHealth
Associate Medical Director
OhioHealth Research Institute
Columbus, Ohio
Assistant Clinical Professor of Medicine
Department of Medicine
University of Toledo Medical Center
Toledo, Ohio
gary.ansel@ohiohealth.com
Disclosures: Consultant or advisory boards for Medtronic, Boston Scientific Corporation, Abbott Vascular, Surmodics, Cook Medical, CR Bard, and Philips.



Gunnar Tepe, MD, PhD

Chief, Diagnostic and Interventional Radiology
RoMed Klinikum
Rosenheim, Germany
gunnar.tepe@ro-med.de
Disclosures: Study support from B. Braun Melsungen AG, Biotronik, Boston Scientific Corporation, Gore & Associates, Medtronic, Cardiovascular Systems Inc., and Shockwave Medical, Inc.; advisory board for B. Braun Melsungen AG and Medtronic.



John R. Laird, MD

Adventist St. Helena Hospital
St. Helena, California
Disclosures: Consultant/advisory board member for Abbott Vascular, Bard Peripheral Vascular, Boston Scientific Corporation, and Medtronic.



Thomas Zeller, MD, PhD

Department of Angiology
Universitäts-Herzzentrum
Freiburg-Bad Krozingen
Bad Krozingen, Germany
Disclosures: Honoraria received from Abbott Vascular, Veyan, Biotronik, Boston Scientific Corporation, Cook Medical, Gore & Associates, Medtronic, Philips-Spectranetics, TriReme, and Shockwave; consulted for Boston Scientific Corporation, Cook Medical, Gore & Associates, Medtronic, Spectranetics, Veyan, Intact Vascular, B. Braun, Shockwave, Bayer, and Vesper Medical; research, clinical trial, or drug study funds received from 480 biomedical, Bard Peripheral Vascular, Veyan, Biotronik, Cook Medical, Gore & Associates, Medtronic, Philips, Terumo, TriReme, Shockwave, Med Alliance, Intact Vascular, and B. Braun; common stock of Veyan and QT Medical.